SPINE Volume 25, Number 20, pp 2663–2667
©2000, Lippincott Williams & Wilkins, Inc.

Incidental Durotomy in Spine Surgery

Frank P. Cammisa, Jr., MD, Federico P. Girardi, MD, Poorab K. Sangani, BA, Hari K. Parvataneni, MD, Stefan Cadag, BS, and Harvinder S. Sandhu, MD

Study Design. Retrospective review of a large series of patients who underwent spinal surgery at a single institution during a 10-year period.

Objectives. To further clarify the frequency of incidental durotomy during spine surgery, its treatment, associated complications, and results of long-term clinical follow-up.

Summary of Background Data. Incidental durotomy is a relatively common occurrence during spinal surgery. There remains significant concern about it despite reports of good associated clinical outcomes. There have been few large clinical series on the subject.

Methods. A retrospective review was conducted of clinical and surgical records and radiographic data for consecutive patients who underwent spinal surgery performed by the two senior surgeons from January 1989 through December 1998.

Results. A total of 2144 patients were reviewed, and 74 were found to have dural tears occurring during or before surgery. Incidental durotomy occurred at the time of surgery in 66 patients (3.1% overall incidence). Incidence varied according to the specific procedure performed but was highest in the group that underwent revision surgery. The incidence of clinically significant durotomies occurring during surgery but not identified at the time was 0.28%. All dural tears that occurred during surgery and were recognized (60 of 66) were repaired primarily. Pseudomeningoceles developed in five of the remaining six patients. All six patients had subsequent surgical repair of dural defects because of failure of conservative therapy. A mean follow-up of 22.4 months was available and showed good long-term clinical results for all patients.

Conclusions. Incidental durotomy, if recognized and treated appropriately, does not lead to long-term sequelae. [Key words: complication, dural tear, incidence, incidental durotomy, spine surgery] **Spine 2000;25:2663–2667**

Incidental durotomy is an unintended tear of the dura mater during surgery or other invasive extradural procedures such as epidural injections. There may also be defects of the dura that remain unhealed after myelography. Durotomies, whether pre-existing or occurring at surgery, are undesirable but relatively commonplace in spine surgery. The incidence or prevalence of incidental durotomy is variable according to the series reviewed as well as according to the type of surgical procedure. Wang et al,[9] in review of 641 patients who underwent lumbar decompression, reported that 14% of patients sustained intraoperative durotomies. Jones et al,[6] in a review of 450 patients who underwent lumbar spine surgery, reported a 4% rate of incidental durotomies recognized at surgery. Incidental durotomy has been described as more likely to occur during surgery at spinal levels with existing scar tissue from prior surgery or irradiation.[8,11]

There have been reports demonstrating good results after surgical repair of durotomies.[2,3,7] Also, there have been reports demonstrating comparable long-term outcomes between patients treated successfully for incidental durotomies at surgery and those having surgery without durotomies.[6,9] Despite these reports and the relative frequency of durotomies, there remains significant concern on the part of surgeons and patients related to patient outcomes and medicolegal implications. Goodkin and Laska,[4] in a review of 146 malpractice cases relating to lumbar spine surgery, reported that incidental durotomy was the second most frequent occurrence. In all cases, patients had associated alleged complication or sequelae. Based on their review, they suggested that incidental durotomy cannot be considered an entirely benign event.

The purpose of the current study was to further clarify incidental durotomy in terms of its incidence; associated surgical procedures and treatment; short-term postoperative sequelae, including headaches and wound infection; and long-term postoperative sequelae, including persistent cerebrospinal fluid (CSF) leak, pseudomeningocele, neurologic deficit, and arachnoiditis.

Materials and Methods

Patients' records, operative notes, and radiographic images of all consecutive patients who underwent spine surgery performed by the two senior surgeons between January 1989 and December 1998 were retrospectively reviewed by a single independent observer. Patients treated for durotomies sustained during surgery at other institutions were excluded. Data reviewed included demographic data, diagnoses, details of surgery, mechanism of durotomy, treatment, and clinical evolution.

Results

A total of 2144 patients were reviewed. Of these, 422 underwent cervical surgery (338 anterior and 84 posterior), 7 underwent posterior thoracic surgery, and 1715 underwent lumbosacral surgery (1646 posterior and 69 anterior). Durotomies were identified in 74 patients with a mean age of 59.9 years (range, 16–83 years). Thirty-seven of these patients were male (50.0%). Twenty-eight of the 74 patients (37.8%) had had surgery, ranging from 1 to 6 procedures. Incidental durotomy occurred at

From the SpineCare Institute, Hospital for Special Surgery, New York, New York.
Acknowledgment date: November 5, 1999.
First revision date: February 16, 2000.
Acceptance date: March 27, 2000.
Device status category: 1.
Conflict of interest category: 12.

Table 1. Incidence of Incidental Durotomy According to Surgical Procedure

Surgical Procedure	Total Number	Incidental Durotomy	Incidence
Decompression only	1175	37	3.1%
Decompression and fusion without instrumentation	205	2	1.0%
Decompression and fusion with instrumentation	502	10	2.0%
Revision spine surgery	209	17	8.1%

the time of surgery in 66 of the 2144 patients (3.1% overall incidence). The incidence varied according to the specific procedure performed (Table 1) but was highest in the group that underwent revision surgery. Of the remaining 8 patients, durotomies recognized at the time of surgery resulted from preoperative myelography in 7 patients and from epidural steroid injections in 1 patient. Two of the 66 incidental durotomies occurring during surgery occurred during cervical spine surgery (1 during anterior cervical decompression and fusion, and the other during posterior decompression and fusion). All other incidental durotomies occurred in the lumbar spine. No incidental durotomies were associated with thoracic spine procedures.

Diagnosis

Of the 74 patients, 8 with durotomies before surgery and 60 of the 66 with incidental durotomies that occurred during surgery were recognized at the time of surgery. In the remaining 6 patients, incidental durotomies were diagnosed subsequent to surgery at an average interval of 20.8 days (range, 5–45). Of these 6 patients, 2 had persistent headache; 1 had persistent postural headaches, symptoms and signs of meningeal irritation, and soft tissue fullness at the surgical site; 2 had neurologic deficit; and 1 had visible CSF leak. Magnetic resonance imaging (MRI) was used for diagnosis of pseudomeningocele (with a presumption of durotomy) in 4 of these patients, computed tomographic (CT) myelography in 1 (Figure 1), and positive identification of CSF in lumbar drainage in 1. Five of these 6 patients had diagnoses of pseudomeningocele and the other of a cerebrospinal fluid leak only. The incidence of clinically significant durotomies occurring during surgery but unrecognized was 0.28%.

Repair

Sixty of the 66 incidental durotomies that occurred during surgery and 7 of the 8 durotomies that occurred before surgery were repaired at the time of identification during surgery. In one patient, the durotomy (located on the nerve root sleeve) occurred during preoperative epidural steroid injection. It was recognized during surgery but was not repaired because of the potential risk of fibrosis and scarring of the nerve root at the repair site.

For all tears, repair consisted of direct suturing of the defect using 5-0 prolene suture material with a running, locked technique. Depending on several factors including the size of the defect, quality of repair, and soft tissue quality, an intraoperative decision was made regarding augmentation of the repair. If indicated, muscle grafts, fat grafts, fibrin patches (obtained during surgery from autologous blood), fibrin glue (obtained from homologous blood), or gelfoam were used for this purpose, in decreasing order of preference. Muscle or fat grafts were placed over defects in 10 patients. Fibrin patches were used in 17 patients, and fibrin glue in another 17. In all cases of repair, the defects were deemed watertight to Valsalva maneuver before closure of the fascia and skin. The position of the operating table was changed if necessary, to facilitate repair of the durotomy. The Trendelenburg position was used for lumbar surgery and the reverse Trendelenburg position for cervical surgery. The table was returned to the neutral position during assessment of the repair by Valsalva maneuver.

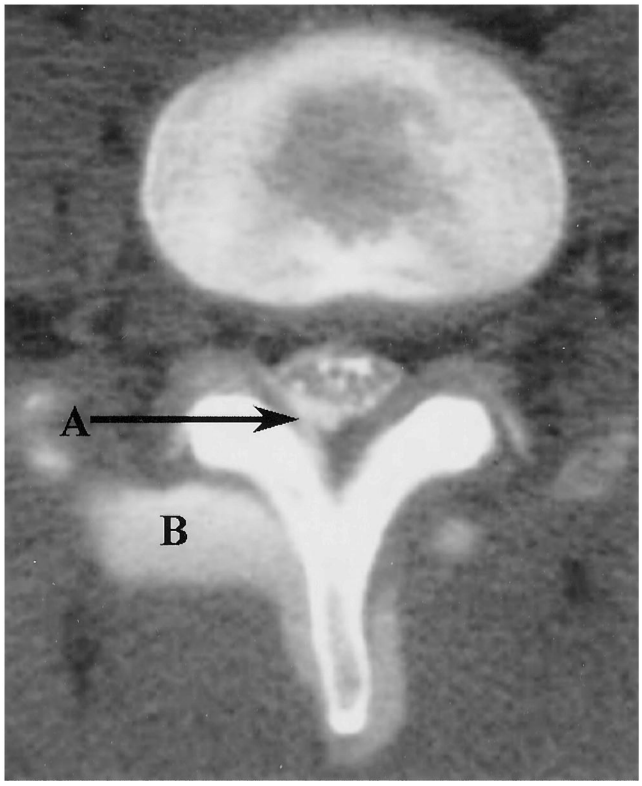

Figure 1. Computed tomographic myelography showing leakage of radiocontrast dye through a lumbar dural defect (**A**) and into surrounding tissues (**B**).

Muscle closure was achieved with no. 1 vicryl sutures (Ethicon, Inc., Johnson & Johnson, Skillman, NJ) using a simple, interrupted technique. Fascial closure was achieved with No. 1 vicryl sutures using both an interrupted figure-eight closure technique and an intervening, continuous technique. Skin closure consisted of interrupted mattress-type sutures using 3-0 nylon sutures as well as intervening, continuous sutures using 3-0 prolene sutures.

Use of subfascial drains was dependent on the procedure performed as well as the degree of intraoperative

blood loss. All patients who underwent fusion with satisfactory repair of durotomies had active (suction) subfascial drains inserted for lumbar procedures and passive (nonsuction) subfascial drains for cervical procedures. Patients who underwent decompression only with satisfactory repair of durotomies but with significant intraoperative blood loss had similar drains inserted. Of 39 patients who underwent primary or revision decompression, 36 had drains inserted. No drains were used in patients who underwent discectomy only. In all other patients, the degree of intraoperative blood loss, size of the durotomy, quality of repair, and tissue quality were factored into decisions regarding use of drains. Judgment of the surgeon was used in all cases for these decisions. Recognized risks associated with active drainage devices in the setting of durotomy such as durocutaneous fistulas and cerebellar herniation through the foramen magnum were weighed against the risk of excessive blood loss and hematoma formation. Drains were kept in place for approximately 2 days in all patients.

Numerous considerations including the size of the durotomy, quality of repair achieved, tissue quality and postoperative clinical course were factored into determination of the length of bed rest required after surgery. Bed rest ranging from 3 to 5 days after surgery was prescribed in all patients. Antibiotic prophylaxis consisted of a 24–48-hour course of broad-spectrum antibiotics starting just before surgery. This protocol is used routinely by the senior authors.

In all five patients with incidental durotomies undetected during surgery and subsequent pseudomeningocele, the symptoms failed to resolve after conservative management, and reoperation was elected in each instance. At the time of reoperation, pseudomeningoceles were confirmed and repaired in all five patients. The remaining patient with incidental durotomy undetected at surgery was initially treated conservatively. The clinical course was complicated, however, by a deep wound infection. During surgical débridement 10 days after surgery, a dural defect was sought, but there was no evidence of cerebrospinal fluid leakage, even under Valsalva maneuver. During a second débridement 3 days later, a 1.5-cm midline dural defect was noted, and the tissue quality of the meninges was thought to be poor with the dura mater being attenuated. Surgical débridement and dural repair were undertaken. A pseudomeningocele subsequently developed that was treated successfully conservatively. Follow-up MRI showed resolution of the pseudomeningocele. Subsequent surgery for a contralateral disc herniation 4 months after the first procedure showed no evidence of pseudomeningocele.

Surgical repair in these six patients was performed as described earlier. Fibrin patches were also placed in two patients, fibrin glue and gelfoam in one, a fascial graft in one, and a muscle graft in the remaining one. Skin and fascial closure were performed as described earlier after the repairs were deemed watertight to Valsalva maneuver.

Sequelae

Follow-up data were available for the eight patients with durotomies occurring before surgery and 64 of the 66 patients with incidental durotomies occurring during surgery. Most recent follow-up was at an average of 22.4 months (range, 4.0–119 months).

Of the 67 patients in which durotomy was recognized and repaired at the time of primary surgery (60 patients with incidental durotomy occurring at surgery plus 7 with durotomy occurring before surgery), two patients reported headaches after surgery. In both, the headaches resolved spontaneously after bed rest in the hospital before discharge. In neither patient did the headaches recur, nor was further work-up warranted. A superficial wound infection occurred in 1 of these patients (1.5% of occurrences repaired at identification), whereas deep wound infections occurred in 4 patients (6.0% of cases repaired at identification). The superficial wound infection was successfully managed with antibiotic therapy, whereas the deep wound infections were successfully managed with wound débridement and antibiotic therapy. All 5 of the patients with courses complicated by wound infections achieved satisfactory outcomes and did not require further management after resolution of the initial infection. Of these 67 patients, none was found to have any of the following sequelae: persistent recurrent headaches, meningitis, pseudomeningocele, cutaneous fistula, or neurologic deficit.

In the single patient in whom durotomy was recognized at the time of primary surgery but not repaired, the postoperative outcome was complicated by persistent recurrent headaches. Based on clinical suspicion, an MRI was ordered 3 weeks after surgery, and a diagnosis of pseudomeningocele was confirmed. Surgical repair was undertaken. After reoperation, the patient's headaches resolved, and the subsequent course was not complicated by any other significant clinical sequelae.

Of the six patients who underwent surgery for repair of durotomies undetected at surgery or pseudomeningoceles secondary to durotomies undetected at surgery, two experienced deep wound infections that necessitated antibiotic therapy and surgical débridement. After initial management these patients recovered fully and had a satisfactory postoperative course.

In all instances, reoperation was successful; none of these patients experienced long-term sequelae.

Eighteen patients had further surgery or radiologic investigation (MRI or CT myelography) for reasons unrelated to the durotomies. None of these patients was found to have evidence of pseudomeningocele or arachnoiditis by radiography or during surgery.

■ Discussion

Jones et al[6] compared long-term clinical outcomes of 17 patients in whom durotomies were identified and successfully repaired at primary surgery with a matched control group who had no durotomies in surgery. Outcome questionnaires were incorporated into data collec-

tion. The authors reported no statistically significant differences between the two groups in outcomes and concluded that durotomies recognized and repaired during surgery do not increase morbidity or affect clinical outcomes.

In a recent report, Wang et al[9] described a large series of unintended durotomies secondary to lumbar spinal surgery that were repaired primarily. They found that, despite the 14% rate of unintended durotomy (88/641 patients), significant morbidity in the immediate postoperative period (including headaches and persistent CSF leak) occurred in only 10 patients. Moreover, they found that postoperative headaches resolved after a short course of bed rest, and both incidences of persistent CSF leak were successfully managed with reoperation. They noted greater frequency of durotomies in revision surgeries and reported that durotomies recognized during surgery could be treated successfully with primary repair and bed rest. Finally, they concluded that incidental durotomy does not adversely influence long-term results of spine surgery.

Eismont et al[2] advocated careful and complete closure of durotomies recognized at the time of surgery. In their study, they recognized the possibility in unrepaired durotomy of CSF fistulas with predisposition to meningitis as well as the possibility of pseudomeningocele with risk of unremitting back pain, headaches, and nerve root entrapment. They found that bed rest, without surgical management, was an ineffective and ultimately unsuccessful method of treatment for unrepaired durotomy. They suggested that small durotomies be repaired with either running locked sutures or simple sutures using fat graft. In the case of larger defects, they recommend fascial grafts secured by interrupted sutures. Valsalva maneuver was recommended to check for the completeness of repair. Finally, they advised against placement of subfascial drains in deference to the possibility of formation of durocutaneous fistula.

On this last point, Wang et al[9] found that subfascial drains did not lead to the formation of durocutaneous fistulas in any of the patients in their series. In the current series, no patients experienced such sequelae associated with subfascial drains. If indicated, subfascial drains may be used in the setting of durotomies, provided that adequate repair of the tear has been achieved and the tissue quality is satisfactory.

Cain et al[1] reported on the healing of surgically created and repaired dural defects in adult beagle dogs. They found that primary fibroblastic bridging was not observed until postoperative day 6, and ablation was not observed until postoperative day 10. Some spine surgeons consider these findings when making decisions regarding length of bed rest after incidental durotomy. It is thought that reducing hydrostatic pressure of cerebrospinal fluid by bed rest facilitates faster healing of the dura. Hodges et al,[5] in a retrospective review of 20 patients with incidental durotomy repaired during surgery, reported that the majority of patients with incidental durotomy can be treated effectively with standard dural repair techniques, but extended bed rest is not necessary. The patients in their series ambulated according to standard postoperative protocols but were instructed to rest if symptoms developed.

Weinstein et al[10] reported an overall infection rate of 2.1% in a separate review of 1594 of the patients in this series (from January 1989 through June 1996). In the current series, a higher rate of deep wound infection was observed (8.1% of 74 patients) in the subgroup of patients with durotomies. With the available data and small sample size, statistical significance was not reached, and the authors could not conclude that there is an increased risk of wound infection with incidental durotomy. Because the incidence of incidental durotomy is highest in patients who undergo revision surgery (Table 1), the rate of wound infection may be attributable to the greater complexity and length of the revision surgeries.

The authors calculated the rate of clinically significant durotomies that were not detected at surgery to be 0.28%. However, the true incidence of unidentified durotomies may be difficult to obtain, because the majority of patients are asymptomatic.[8]

Based on the current data, the incidence of unintended durotomy at the time of surgery is relatively low (3.1%) but increases with complexity of surgery. Good long-term clinical results were noted in all patients with durotomies repaired at identification and are comparable to long-term results of patients undergoing similar surgical procedures but without durotomies. This is in keeping with the findings of Wang et al.[9] Good, long-term clinical results were also noted in the six patients with unrecognized incidental durotomies (all repaired surgically). However, it cannot be concluded from the data that surgical repair is indicated in all cases of unrecognized incidental durotomies and sequelae including pseudomeningoceles or durocutaneous fistulas.

In conclusion, incidental durotomy, if recognized and treated appropriately, does not lead to long-term sequelae.

■ Key Points

- Retrospective review of 2144 patients who underwent spinal surgery at a single institution during a 10-year period.
- There was a 3.1% incidence of dural tears occurring at the time of surgery.
- A higher incidence of dural tears was associated with revision surgery.
- Dural tears that were recognized and treated appropriately did not lead to long-term sequelae at a mean follow-up of 22.4 months.

References

1. Cain JE Jr, Lauerman WC, Rosenthal HG, et al. The histomorphologic sequence of dural repair: observations in the canine model. Spine 1991;16;S319–23.
2. Eismont FJ, Wiesel SW, Rothman RH. Treatment of dural tears associated with spinal surgery. J Bone Joint Surg [Am] 1981;63:1132–6.
3. Finnegan WJ, Fenlin JM, Marvel JP, et al. Results of surgical intervention in the symptomatic multiply-operated back patient: analysis of sixty-seven cases followed for three to seven years. J Bone Joint Surg [Am] 1979;61;1077–82.
4. Goodkin R, Laska LL. Unintended "incidental" durotomy during surgery of the lumbar spine: medicolegal implications. Surg Neurol 1995;43:4–12.
5. Hodges SD, Humphreys SC, Eck JC, et al. Management of incidental durotomy without mandatory bed rest: a retrospective review of 20 cases. Spine 1999;24:2062–4.
6. Jones AAM, Stambough JL, Balderston RA, et al. Long-term results of lumbar spine surgery complicated by unintended incidental durotomy. Spine 1989; 14:443–6.
7. Kitchel SH, Eismont FJ, Green BA. Closed subarachnoid drainage for management of cerebrospinal fluid leakage after an operation on the spine. J Bone Joint Surg [Am] 1989;71:984–7.
8. McCormack BM, Zide BM, Kalfas IH. Cerebrospinal fluid fistula and pseudomeningocele after spine surgery. In: Benzel EC, ed. Spine Surgery: Techniques, Complication Avoidance and Management. Philadelphia: Churchill Livingstone, 1999:1465–74.
9. Wang JC, Bohlman HH, Riew DK. Dural tears secondary to operations on the lumbar spine: Management and results after a two-year-minimum follow-up of eighty-eight patients. J Bone Joint Surg [Am] 1998;80:1728–32.
10. Weinstein MA, McCabe JP, Cammisa FP Jr. Post operative spinal wound infection. Proceedings of the 11th Annual Meeting of the North American Spine Society, Vancouver, British, Columbia, Canada; 1996:254.
11. Wiesel SW. The multiply-operated lumbar spine. Instruct Course Lecture. 1985;34:68–77.

Address reprint requests to

Frank P. Cammisa, Jr, MD
SpineCare Institute
Hospital for Special Surgery
535 East 70th Street
New York, NY 10021
cammisaf@hss.edu