

# Evaluation of Synthetic Osteochondral Implants

James L. Cook, DVM, PhD<sup>1</sup> Keiichi Kuroki, DVM, PhD<sup>1</sup> Chantelle C. Bozynski, DVM, MSc<sup>1</sup>  
 Aaron M. Stoker, MS, PhD<sup>1</sup> Ferris M. Pfeiffer, PhD<sup>1</sup> Cristi R. Cook, DVM, MS<sup>1</sup>

<sup>1</sup>Comparative Orthopaedic Laboratory and Missouri Orthopaedic Institute, University of Missouri, Columbia, Missouri

**Address for correspondence** James L. Cook, DVM, PhD, Comparative Orthopaedic Laboratory and Missouri Orthopaedic Institute, University of Missouri, 1100 Virginia Avenue, Columbia, MO 65212 (e-mail: cookjl@health.missouri.edu).

J Knee Surg

## Abstract

This translational animal model study was designed to assess function, bone ingrowth and integration, and joint pathology associated with two different synthetic, bilayered osteochondral implants over a 3-month period after implantation into the femoral condyles of dogs. SynACart-Titanium ( $n = 6$ ) and SynACart-PEEK ( $n = 6$ ) (Arthrex, Naples, FL, and Sites Medical, Columbia City, IN) implants were press-fit into the lateral or medial femoral condyle (alternating location) of purpose-bred adult research dogs. Dogs were humanely euthanized 3 months after surgery and the operated knees were assessed radiographically, arthroscopically, grossly, and histologically. Based on all assessments, both types of implants were well tolerated and safe with no evidence for infection, migration, or rejection. Half of the SynACart-PEEK implants showed radiographic and histologic evidence of poor incorporation with all of these being in the lateral femoral condyle. SynACart-Titanium implants were considered effective in terms of integration into bone, lack of damage to surrounding and apposing articular cartilage, and maintenance of implant integrity and architecture for the duration of the study.

## Keywords

- ▶ knee
- ▶ osteochondral
- ▶ dog
- ▶ femoral condyle
- ▶ synthetic

Patients with focal cartilage defects in the knee can suffer losses in quality of life that are as severe as those with end-stage osteoarthritis.<sup>1</sup> Effective treatment of focal articular cartilage defects continues to present a clinical challenge. Techniques including marrow stimulation, cell-based therapies, autogenous and allogeneic osteochondral grafts, and tissue-engineered constructs are current biologic strategies for surgical treatment of defects in the knee.<sup>2–8</sup> Long-term success rates, availability, financial considerations, and logistical hurdles are some of the factors associated with these biologic strategies that limit their use. Synthetic (artificial) osteochondral implants provide potential solutions to some of these limitations in that they can be manufactured as readily available, cost-effective, off-the-shelf implants of various size and shape to address the common needs in the knee, ankle, and shoulder.

Synthetic (artificial) osteochondral implants have primarily been metal prostheses used for hemiarthroplasty of the hip and shoulder.<sup>9,10</sup> However, use of a metallic inlay prosthesis for treatment of focal femoral condylar cartilage defects was reported to be associated with improvements in pain and function

scores for as long as 6 years in two small case series of middle-aged, well-selected patients.<sup>11,12</sup> To the authors' knowledge, the use of bilayered, synthetic osteochondral implants for treatment of focal cartilage defects has only been previously reported in a single canine study.<sup>13</sup> Although promising results were reported for these implants, translation to clinical use in human patients has not been realized to date.

On the basis of the potential clinical applicability for synthetic osteochondral implants for surgical treatment of focal articular cartilage defects in the knee, we designed a study to evaluate two different synthetic osteochondral implants after implantation into the femoral condyles of dogs. The objective of the study was to assess function, bone ingrowth and integration, and joint pathology associated with the implants over a 3-month period following implantation.

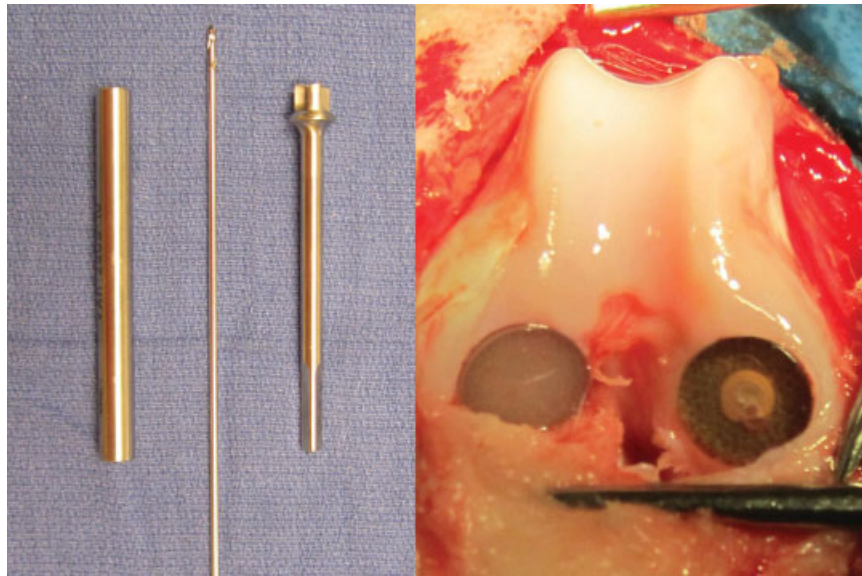
## Materials and Methods

All procedures were approved by the institution's animal care and use committee. Purpose-bred adult research dogs ( $n = 6$ ) (mean body weight = 21.0 kg) were used for this study. On

received  
 May 23, 2013  
 accepted after revision  
 October 27, 2013

Copyright © by Thieme Medical Publishers, Inc., 333 Seventh Avenue, New York, NY 10001, USA.  
 Tel: +1(212) 584-4662.

DOI <http://dx.doi.org/10.1055/s-0033-1361951>.  
 ISSN 1538-8506.



**Fig. 1** Intraoperative images of instrumentation (alignment guide, Beath pin, and reamer) and SynACart-Titanium (left) and SynACart-PEEK (right) osteochondral implants in the lateral and medial femoral condyles, respectively, of a dog.

the day of implantation, dogs were premedicated, anesthetized, and prepared for aseptic surgery of the right hindlimb. The right stifle (knee) of each dog was exposed via lateral parapatellar approach with lateral arthrotomy and medial patellar luxation for access to both femoral condyles. Using implant-specific instrumentation (Arthrex, Naples, FL) consisting of an alignment guide, Beath pin and cannulated and depth-controlled reamer, one 10-mm diameter  $\times$  8-mm-deep socket was created in the weight-bearing portion of each femoral condyle (**Fig. 1**). Each socket was then implanted with one of two different synthetic osteochondral implants using a tamped, press-fit technique. The synthetic osteochondral implants used in this study were 10-mm diameter  $\times$  8-mm-deep bilayered constructs consisting of a surface (chondral) layer of polycarbonate urethane and a bone ingrowth material (osteo layer) of BioSync-Titanium (SynACart-Ti) ( $n = 6$ ) or BioSync-PEEK (SynACart-PEEK) ( $n = 6$ ) (Arthrex and Sites Medical, Columbia City, IN). One implant of each type was placed in each dog's knee and location was alternated between medial and lateral femoral condyles. The surgical wound was closed routinely, postoperative radiographs were obtained, and a soft padded bandage was placed on the operated limb and maintained for 24 hours after surgery. Analgesics were provided for a minimum of 3 days after surgery. Dogs were allowed immediate weight bearing and unrestricted activity in their individual kennels, and enrichment activity in communal areas was allowed after skin suture removal (10 days postoperatively) and continued twice daily for the duration of the study.

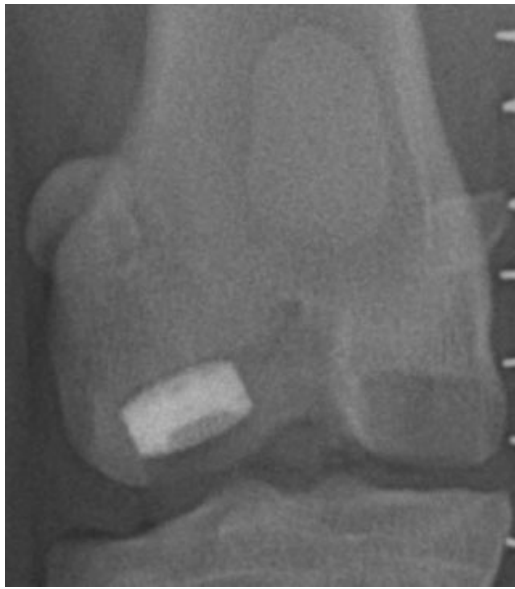Dogs were humanely euthanized 3 months after surgery and orthogonal view radiographs of the operated knees were obtained. Radiographs were assessed by a board-certified veterinary radiologist, blinded to implant type, to assess implant positioning, socket and associated bone appearance, and radiographic evidence of joint pathology. Arthroscopic assessment of all operated knees was then performed by a

board-certified veterinary orthopaedic surgeon, blinded to implant type and location, using standard technique to subjectively evaluate the implants and document any associated joint pathology.<sup>14,15</sup> The operated knees were then carefully dissected and disarticulated to grossly evaluate the implants and all intra-articular tissues. The menisci were carefully removed and the articular surfaces of the tibial condyles were painted with India ink, washed after 60 seconds with tap water, photographed, and examined for retention of ink.

For histologic assessments, the tibial and femoral condyles were harvested, sectioned, and fixed in 10% buffered formalin. After dehydration through a series of graded ethyl alcohol solutions, femoral condyle sections including the implants were embedded in polymethyl methacrylate and sectioned (100  $\mu$ m thick) using a diamond saw and grinder. The sections were stained with Goldner trichrome and toluidine blue. The tibial condyles were decalcified and processed routinely for histologic assessment of hematoxylin and eosin and toluidine blue stained sections. Two board-certified veterinary pathologists who were blinded to implant type and location assessed the histologic sections for subjective determination of the implants and responses of surrounding and apposing cartilage and bone. Specific assessments with respect to the implants included osteoconductivity and integration. Osteoconductivity was defined as the degree of definitive bone ingrowth into the implants and was categorized as poor (< 25%), fair (25–50%), or good (> 50%). Integration was defined as total tissue ingrowth into the implants in conjunction with the presence or absence of associated necrosis, inflammatory or immune cell response, or absence of tissue (interface gap), and was subjectively categorized as poor, fair, or good.

## Results

All implants were placed successfully and all dogs recovered from surgery and were maintained for the intended duration



**Fig. 2** Immediate postoperative anteroposterior radiographic view of SynACart-Titanium (left) and SynACart-PEEK (right) osteochondral implants in the lateral and medial femoral condyles, respectively, of a dog's knee.

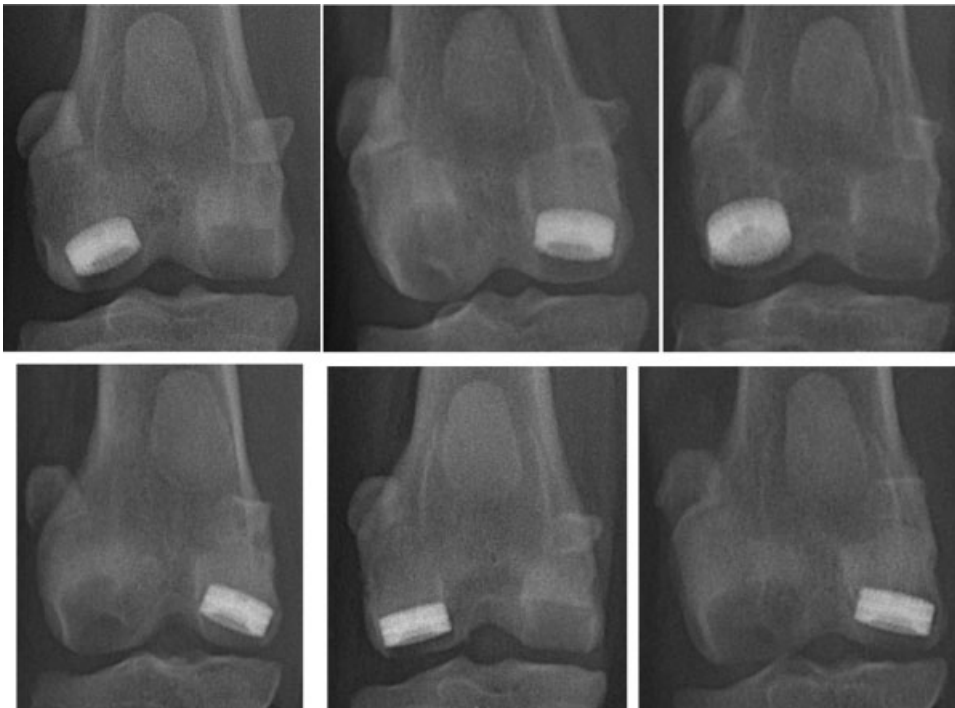
of study without noted complications. Immediate postoperative radiographs showed appropriate placement of all implants (► **Fig. 2**).

Radiographs obtained 3 months after implantation showed evidence for very mild joint effusion in all joints with no evidence for radiographic osteoarthritis such as osteophytosis or joint space collapse. All implants appeared

unchanged with respect to location and orientation. All SynACart-Ti implants showed radiographic evidence for integration into host bone with mild-to-moderate peri-implant sclerosis noted for five of six (83%). Only three of six (50%) of the SynACart-PEEK implants showed evidence for integration into host bone and all of these were in the medial femoral condyle. All SynACart-PEEK implants were associated with moderate-to-severe peri-implant sclerosis with all of those in the lateral femoral condyle showing severe sclerosis. The three SynACart-PEEK implants in the lateral femoral condyle showed radiographic evidence of socket expansion 3 months after implantation (► **Fig. 3**).

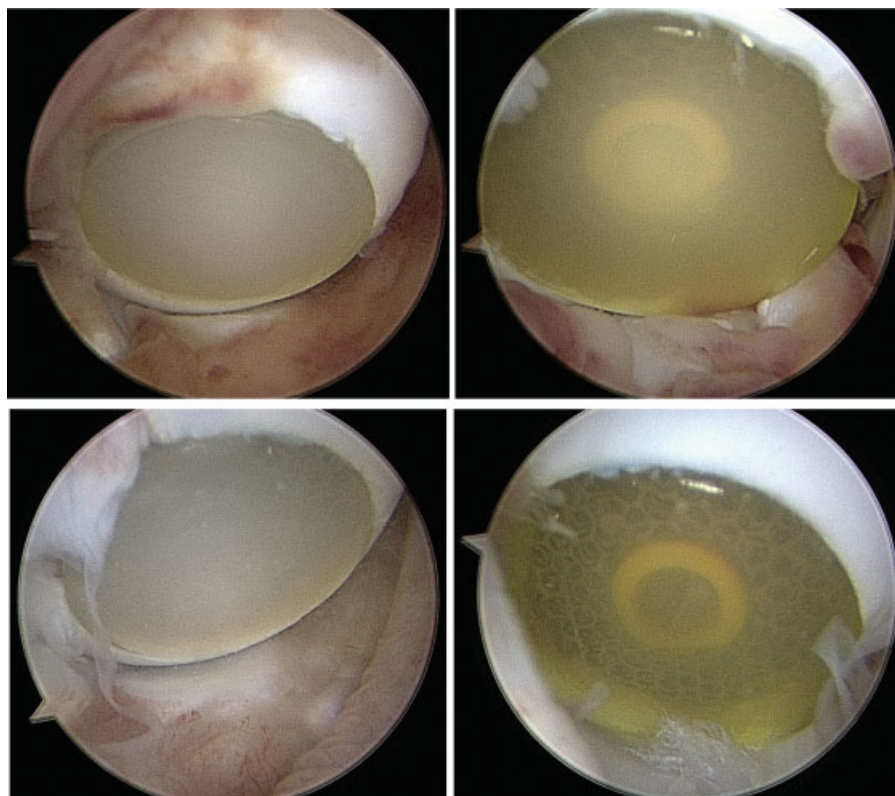
Arthroscopic assessments performed 3 months after implantation showed evidence of mild, focal synovitis in all joints. No arthroscopic evidence for tibial or meniscal damage was noted and no other pathologic changes were seen. Visualization and palpation of the implants revealed maintenance of implant location and orientation, lack of migration or subsidence, and lack of appreciable changes to the architecture and surface characteristics of all implants. All implants were felt to be stable on palpation with a blunt obturator apart from one SynACart-PEEK implant in the lateral femoral condyle of one dog, which could be slightly "pistoned" in its socket. All implants were flush to 0.5 mm proud to surrounding articular cartilage and no evidence for significant peri-implant cartilage pathology was noted (► **Fig. 4**).

Gross assessments of the operated joints showed evidence of mild synovitis and fibrosis associated with the site of arthrotomy and the fat pad in all joints. No cranial (anterior) cruciate ligament, caudal (posterior) cruciate ligament, long



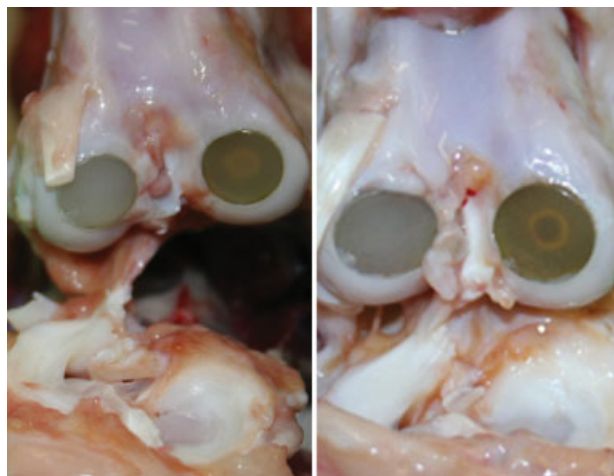
**Fig. 3** Anteroposterior radiographic views of the SynACart-Titanium (radiopaque) and SynACart-PEEK (radiolucent) osteochondral implants in the femoral condyles of all six dogs in this study obtained 3 months after implantation.





**Fig. 4** Representative arthroscopic images of SynACart-Titanium (left) and SynACart-PEEK (right) osteochondral implants in the femoral condyles of dogs in this study obtained 3 months after implantation.

digital extensor tendon, patellar, trochlear groove, or tibial articular cartilage, or meniscal damage was noted in any joint (►Fig. 5). India ink staining of the tibial condyles showed no retention of ink. As noted arthroscopically, all implants were flush to very slightly proud to surrounding articular cartilage and were felt to be stable on palpation apart from one




**Fig. 5** Representative gross images of SynACart-Titanium (left/lateral femoral condyle in both images) and SynACart-PEEK (right/medial femoral condyle in both images) osteochondral implants in the femoral condyles of dogs in this study obtained 3 months after implantation.

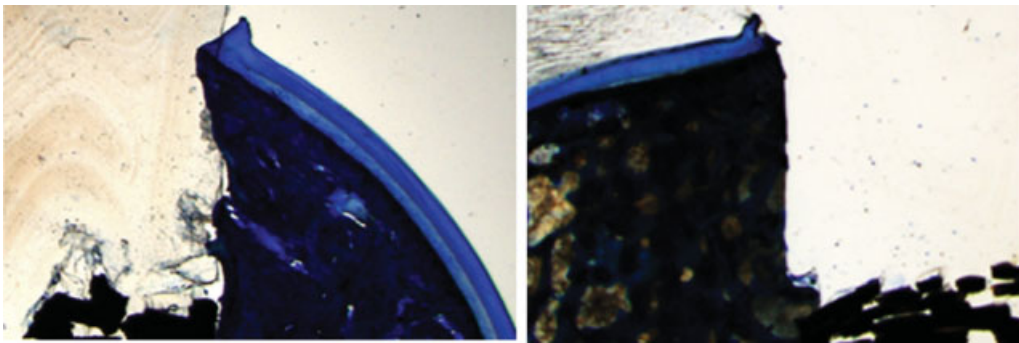
SynACart-PEEK implant in the lateral femoral condyle of one dog. All implants remained in place during sectioning.

Histologic assessments showed maintained integrity and architecture of the surface (chondral) layer for all implants with no evidence for delamination, pitting, fissures, or cracks (►Fig. 6). The interface between implants and native articular cartilage ranged from immediate abutment with no interpositional tissue (2 of 12) to small (< 1 mm) gaps with no interpositional tissue (2 of 12) to small (< 1 mm) gaps filled with interpositional fibrous-fibrocartilage tissue (8 of 12). Peri-implant articular cartilage within the histologic sections examined showed slight disruption at the implant interface with mild loss of proteoglycan staining in some, but no other apparent architectural, extracellular matrix, or cellular pathologic changes (►Fig. 7).

Osteoconductivity of the deep (osseous) layer of the implants ranged from poor (2 of 12) to fair (5 of 12) to good (5 of 12). Integration of the deep (osseous) layer of the implants ranged from poor (1 of 12) to fair (2 of 12) to good (9 of 12). Marrow fibrosis was noted subjacent to the implants in all sections examined and ranged from mild (1 of 12) to moderate (9 of 12) to severe (2 of 12). All poor outcomes and severe marrow changes were associated with SynACart-PEEK implants in the lateral femoral condyle (►Fig. 8). Histologic assessment of the tibial condyles showed no to minimal pathology. When present, the pathologic changes consisted of mild loss of proteoglycan staining and/or surface fibrillations. The most severe changes were seen in the lateral tibial condyle in apposition with the SynACart-PEEK implant with documented instability (►Fig. 9).



**Fig. 6** Representative photomicrographs of the surfaces of SynACart-Titanium (left) and SynACart-PEEK (right) osteochondral implants in the femoral condyles of dogs in this study obtained 3 months after implantation (Goldner stain; original magnification  $\times 1.25$ ).



**Fig. 7** Representative photomicrographs of the cartilage interfaces of SynACart-Titanium (left) and SynACart-PEEK (right) osteochondral implants in the femoral condyles of dogs in this study obtained 3 months after implantation (Toluidine blue stain; original magnification  $\times 1.25$ ).

## Discussion

SynACart-Titanium and SynACart-PEEK bilayered, synthetic osteochondral implants (10 mm diameter) were considered technically feasible for press-fit implantation into the medial and lateral femoral condyles of research dogs. Based on clinical, radiographic, arthroscopic, gross, and histologic assessments, both types of implants were well tolerated and safe with no evidence for infection, migration, or rejection during the 3-month study period. Half of the SynACart-PEEK implants showed radiographic and histologic evidence of poor incorporation (severe sclerosis, socket expansion, poor osteoconductivity, and/or integration) with all of these being in the lateral femoral condyle. SynACart-Titanium implants were considered effective in terms of integration into bone, lack of damage to surrounding and apposing articular cartilage, and maintenance of implant integrity and architecture for the duration of the study.

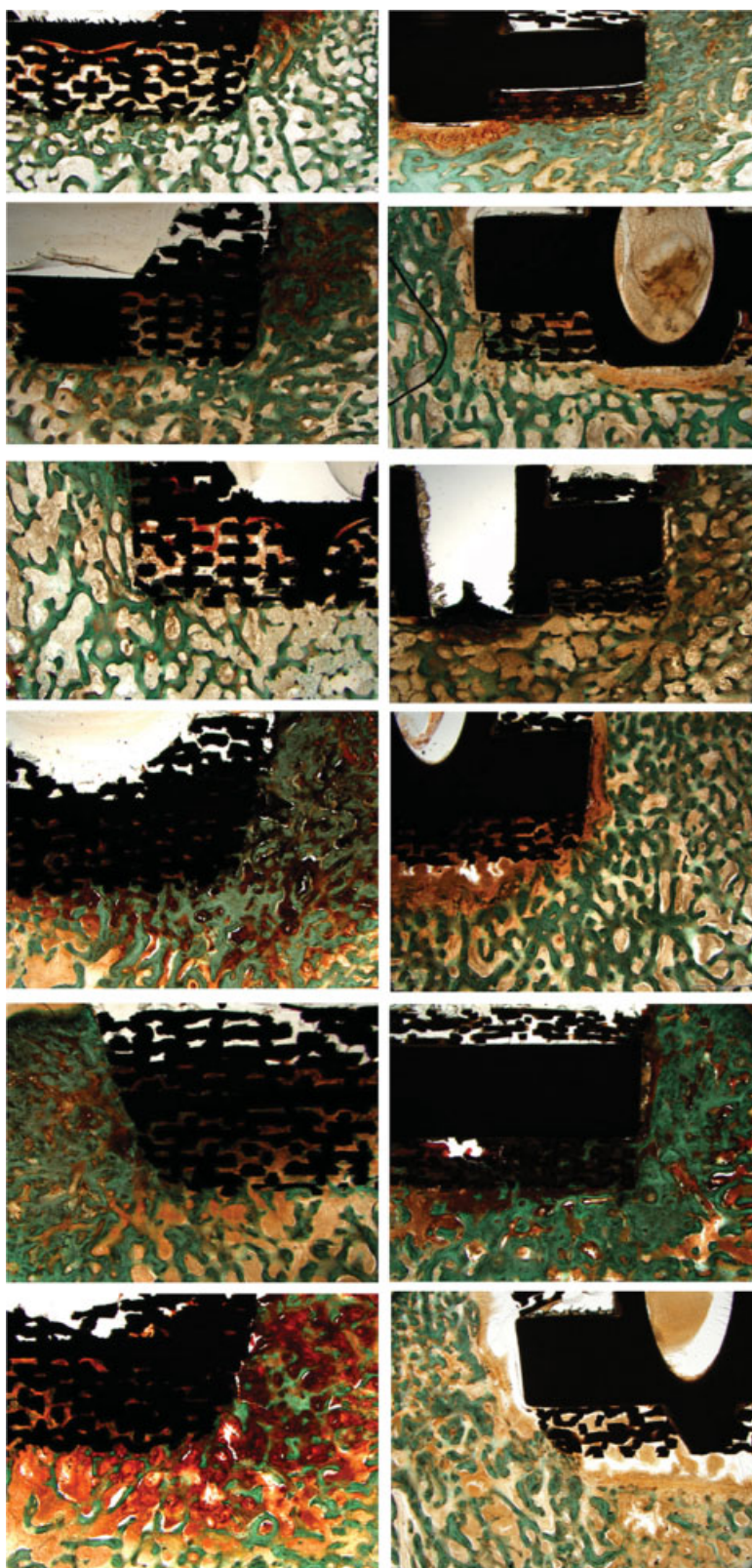
For both types of implants used in this study, lateral femoral condyle implants were judged to have inferior outcomes compared with those in the medial femoral condyle. This is most likely related to the relative size and fit of the implants for the canine lateral femoral condyle. In dogs, the lateral femoral condyle has a more narrow axial-abaxial dimension and smaller radius of curvature than the medial femoral condyle. As such, the 10-mm diameter implants used more closely matched the anatomy of the medial femoral

condyle, likely resulting in more favorable implant loading and performance.

The degree of radiographic sclerosis and marrow fibrosis noted for the majority of the implants is expected in association with the synthetic materials used and altered subchondral bone loading. Mild-to-moderate sclerosis and fibrosis are not considered pathologic for this time point after implantation. However, the severe sclerosis and marrow fibrosis seen in association with SynACart-PEEK implants in the lateral femoral condyle was considered indicative of pathology. This was supported by the histologic findings of poor osteoconductivity and/or integration for these implants, as well as the arthroscopic and gross findings of instability for the implant with the most severe radiographic and histologic changes. These findings suggest that clinical outcome measures such as radiographic imaging and arthroscopic assessments can be used to determine implant status for longitudinal *in vivo* studies.

Oka et al<sup>13</sup> investigated alumina, titanium, and polyvinyl alcohol (PVA) hydrogel-titanium fiber mesh osteochondral implants in the femoral condyles of dogs for 8 and 24 weeks after implantation. At both time points, these investigators reported marked gross and histologic changes in apposing tibial articular cartilage associated with all of the alumina and titanium implants, which has also been reported for other metal osteochondral resurfacing prosthesis.<sup>16-18</sup> In contrast, the bilayered PVA-titanium osteochondral implants were associated with only slight changes in apposing tibial cartilage,



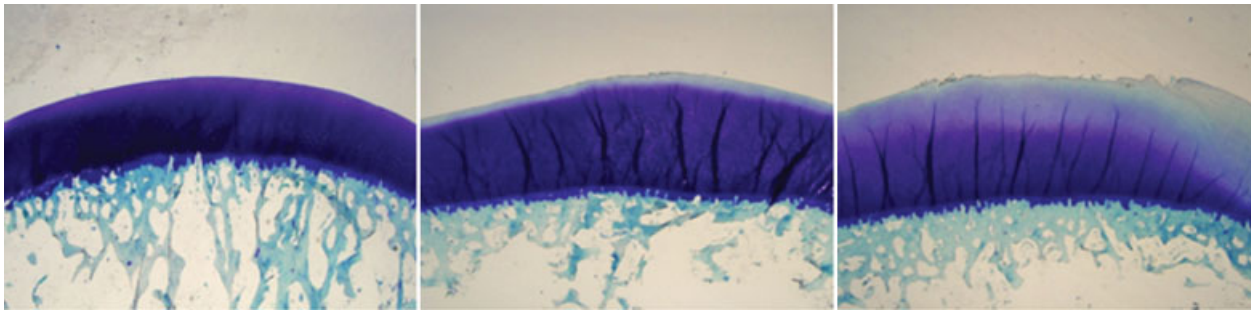


**Fig. 8** Photomicrographs of the osseous layers of SynACart-Titanium (left) and SynACart-PEEK (right) osteochondral implants in the femoral condyles of all six dogs in this study obtained 3 months after implantation (Goldner stain; original magnification  $\times 1.25$ ).

and were reported to show abundant new bone ingrowth into the pores of the titanium mesh by 8 weeks with further lamellar bone remodeling at 24 weeks post-implantation. However, a cyst-like gap was present between the surrounding

normal articular cartilage and the PVA hydrogel at both time points after implantation.

In the present study, consistent bone ingrowth was noted for all SynACart-Titanium implants and surrounding articular



**Fig. 9** Representative photomicrographs of tibial condyles demonstrating the spectrum of changes observed in articular cartilage that was in apposition to SynACart-Titanium and SynACart-PEEK osteochondral implants in the femoral condyles of dogs in this study obtained 3 months after implantation (Toluidine blue stain; original magnification  $\times 1.25$ ).

cartilage was well preserved with no cyst-like gaps seen for any of the implants. Tibial articular cartilage in apposition to the implants also showed little to no pathologic change over the 3-month study period, and no gross meniscal pathology was noted. The surface (chondral) layer of all implants showed no gross or histologic evidence for delamination, pitting, fissures, or cracks. The chondral layer for SynACart implants is composed of medical-grade polycarbonate-based thermoplastic urethane (PCU) (ChronoFlex C; AdvanceSource Biomaterials, Wilmington, MA) that was fabricated and molded with mechanical interdigitation to the osseous base (BioSync; Sites Medical, Columbia City, IN). The PCU surface layer is designed to resist surface degradation and fissuring, and has been reported to be biocompatible, chemically and physically stable, and have excellent wear and bearing properties *in vivo*.<sup>19–21</sup> The data from the present study suggest that this material was effective in maintaining these characteristics when used as a focal cartilage resurfacing material in the femoral condyle of dogs.

Limitations of the present study include the use of dogs with normal knees, a single, short-term endpoint, and subjective outcomes measures. In some ways, normal knees provide a more challenging setting for assessing osteochondral implants, in that even subtle changes to any facet of joint health are recognizable. With the single, short-term endpoint used in this study, wear characteristics of the implants cannot be provided. From the present data, we can only state that surface architecture of all implants was maintained with no evidence for delamination, pitting, fissures, or cracks, and that only focal, mild synovitis was noted 3 months after implantation. While the outcome measures employed in this study were subjective in nature, they covered a complete spectrum of modalities from basic science assessments to clinically relevant diagnostics, the investigators were blinded to implant type, and results from each outcome measure corresponded well with each of the others. So, despite these limitations, this study provides novel and valid data regarding the use of these bilayered, synthetic osteochondral implants for treatment of femoral condylar defects in the knees of research dogs.

In conclusion, the data from this study suggest that SynACart-PEEK osteochondral implants require modification

and further assessment before clinical testing could be recommended. However, SynACart-Titanium bilayered, synthetic osteochondral implants appear safe for clinical application for treatment of focal cartilage defects in the femoral condyle.

## References

- 1 Heir S, Nerhus TK, Røtterud JH, et al. Focal cartilage defects in the knee impair quality of life as much as severe osteoarthritis: a comparison of knee injury and osteoarthritis outcome score in 4 patient categories scheduled for knee surgery. *Am J Sports Med* 2010;38(2):231–237
- 2 Gomoll AH. Microfracture and augments. *J Knee Surg* 2012;25(1):9–15
- 3 Kon E, Filardo G, Di Martino A, Marcacci M. ACI and MACI. *J Knee Surg* 2012;25(1):17–22
- 4 Farr J, Cole BJ, Sherman S, Karas V. Particulated articular cartilage: CAIS and DeNovo NT. *J Knee Surg* 2012;25(1):23–29
- 5 Dhollander AA, Guevara Sánchez VR, Almqvist KF, Verdonk R, Verbruggen G, Verdonk PC. The use of scaffolds in the treatment of osteochondral lesions in the knee: current concepts and future trends. *J Knee Surg* 2012;25(3):179–186
- 6 McCoy B, Miniaci A. Osteochondral autograft transplantation/mosaicplasty. *J Knee Surg* 2012;25(2):99–108
- 7 Bugbee W, Cavallo M, Giannini S. Osteochondral allograft transplantation in the knee. *J Knee Surg* 2012;25(2):109–116
- 8 O'Connell GD, Lima EG, Bian L, et al. Toward engineering a biological joint replacement. *J Knee Surg* 2012;25(3):187–196
- 9 Dalldorf PG, Banas MP, Hicks DG, Pellegrini VD Jr. Rate of degeneration of human acetabular cartilage after hemiarthroplasty. *J Bone Joint Surg Am* 1995;77(6):877–882
- 10 Rees JL, Dawson J, Hand GC, et al. The use of patient-reported outcome measures and patient satisfaction ratings to assess outcome in hemiarthroplasty of the shoulder. *J Bone Joint Surg Br* 2010;92(8):1107–1111
- 11 Bollars P, Bosquet M, Vandekerckhove B, Hardeman F, Bellemans J. Prosthetic inlay resurfacing for the treatment of focal, full thickness cartilage defects of the femoral condyle: a bridge between biologics and conventional arthroplasty. *Knee Surg Sports Traumatol Arthrosc* 2012;20(9):1753–1759
- 12 Becher C, Kalbe C, Thermann H, et al. Minimum 5-year results of focal articular prosthetic resurfacing for the treatment of full-thickness articular cartilage defects in the knee. *Arch Orthop Trauma Surg* 2011;131(8):1135–1143
- 13 Oka M, Chang Y-S, Nakamura T, Ushio K, Toguchida J, Gu H-O. Synthetic osteochondral replacement of the femoral articular surface. *J Bone Joint Surg Br* 1997;79(6):1003–1007

- 14 Mahn MM, Cook JL, Cook CR, Balke MT. Arthroscopic verification of ultrasonographic diagnosis of meniscal pathology in dogs. *Vet Surg* 2005;34(4):318–323
- 15 Cook JL, Kuroki K, Visco D, Pelletier J-P, Schulz L, Lafebber FP. The OARSI histopathology initiative—recommendations for histological assessments of osteoarthritis in the dog. *Osteoarthritis Cartilage* 2010;18(Suppl 3):S66–S79
- 16 Custers RJ, Saris DB, Dhert WJ, et al. Articular cartilage degeneration following the treatment of focal cartilage defects with ceramic metal implants and compared with microfracture. *J Bone Joint Surg Am* 2009;91(4):900–910
- 17 Custers RJ, Creemers LB, van Rijen MHP, Verbout AJ, Saris DBF, Dhert WJA. Cartilage damage caused by metal implants applied for the treatment of established localized cartilage defects in a rabbit model. *J Orthop Res* 2009;27(1):84–90
- 18 Kirker-Head CA, Van Sickle DC, Ek SW, McCool JC. Safety of, and biological and functional response to, a novel metallic implant for the management of focal full-thickness cartilage defects: preliminary assessment in an animal model out to 1 year. *J Orthop Res* 2006;24(5):1095–1108
- 19 Khan I, Smith N, Jones E, Finch DS, Cameron RE. Analysis and evaluation of a biomedical polycarbonate urethane tested in an in vitro study and an ovine arthroplasty model. Part I: materials selection and evaluation. *Biomaterials* 2005;26(6):621–631
- 20 Khan I, Smith N, Jones E, Finch DS, Cameron RE. Analysis and evaluation of a biomedical polycarbonate urethane tested in an in vitro study and an ovine arthroplasty model. Part II: in vivo investigation. *Biomaterials* 2005;26(6):633–643
- 21 Kurtz SM, Siskey R, Reitman M. Accelerated aging, natural aging, and small punch testing of gamma-air sterilized polycarbonate urethane acetabular components. *J Biomed Mater Res B Appl Biomater* 2010;93(2):442–447